

Patient Details

Date: _____ DOB: _____ Medicare No: _____

Name: _____

Address: _____ Phone: _____

For all appointments

Ph: 4965 6200

Fax: 4942 7506

Email: mackay@qldxray.com.au

Diagnostic Request. Reason for referral and clinical history.

GP Medicare rebateable studies are below. Please tick which items apply. (**3 services per 12 months)

MRI Person OVER 16

Head - 63551**

- ☐ Unexplained seizure
- ☐ Unexplained chronic headache

Spine - 63554**

- ☐ For suspected cervical radiculopathy

Spine - 63557**

- ☐ For suspected cervical spine trauma

Knee inability to extend after acute trauma - 63560** (50 years and over not eligible)

- ☐ Inability to extend the knee suggesting the possibility of acute meniscal tear ☐ Clinical findings suggesting ACL tear

MRI Person UNDER 16

Head - 63507**

- ☐ Unexplained seizure
- ☐ Unexplained headache with pathology
- ☐ Paranasal sinus pathology unresponsive to therapy

Spine following prior radiology - 63510**

- ☐ Significant trauma
- ☐ Unexplained neck/back pain with neurological signs
- ☐ Unexplained back pain with significant pathology

Hip following prior radiology - 63516

- ☐ Suspected septic arthritis ☐ Suspected Perthes disease
- ☐ Suspected slipped capital femoral epiphysis

Elbow following prior radiology - 63519

- ☐ Suspected significant fracture or avulsion

Wrist following prior radiology - 63522

- ☐ Suspected scaphoid fracture

Knee - 63513**

- ☐ For internal joint derangement

Image Guided Injections - please tick options below. The Radiologist will determine the best modality to use based on the clinical indication.

Facets, side ☐ Left ☐ Right

- ☐ Levels _____

Nerve roots, side ☐ Left ☐ Right

- ☐ Levels _____

Epidural steroid injection

- ☐ Level _____

Elbow, side ☐ Left ☐ Right

- ☐ Common extensor origin ☐ Elbow joint

- ☐ Olecranon bursa ☐ Other _____

Wrist, side ☐ Left ☐ Right

- ☐ Carpal tunnel ☐ Scapholunate joint

- ☐ APL/EPB (De Quervain's) ☐ Other _____

Shoulder, side ☐ Left ☐ Right

- ☐ Bursa ☐ Glenohumeral joint

- ☐ Acromioclavicular joint

Knee, side ☐ Left ☐ Right

- ☐ Joint ☐ Other _____

Hip, side ☐ Left ☐ Right

- ☐ Trochanteric bursa ☐ Hip joint

- ☐ Other _____

Ankle/foot, side ☐ Left ☐ Right

- ☐ Talocrural joint ☐ Subtalar joint

- ☐ Morton's neuroma ☐ Plantar fascia

- ☐ Achilles

I confirm the patient is eligible to participate in the National Lung Cancer Screening Program (NLCSP)

- ☐ 57410 Low-dose CT scan of chest for NLCSP - Initial or 2 Year Re-Scan

- ☐ Family history of lung cancer in a first-degree relative (includes parents, siblings or children)

- ☐ 57413 Low-dose CT scan of chest for NLCSP - Interval or Follow-up

Myocardial Perfusion Studies (Nuclear Medicine) - 24 mths+ since prior MPS, age 17+

- 61329 ☐ The patient has symptoms of cardiac ischaemia; and one of the following applies:

- ☐ Stress echo unlikely to be adequate due to a) body habitus, including obesity, b) arrhythmia, including atrial fibrillation
- ☐ Unable to exercise to the extent required for a stress echo to provide adequate information
- ☐ Failed previous stress echo (in last 24 months)

Referring Practitioner's Details

Practitioner's Name: _____

Address: _____

Signature: _____

Copy to: _____

Thank you for referring your patient to Queensland X-Ray.

Queensland X-Ray Internal Use Only

Medical Imaging Final Check

Yes No

Pregnant ☐ ☐Front Office Check ☐Patient Identification verified ☐Procedure and consent verified ☐Correct side and site verified ☐

Correct patient data and side markers

Tech initials: _____

Team leader signature: _____

BMD - subject to Medicare criteria (Please tick box below)

- 12321** ☐ 12 mths+ since prior BMD. 12 mths since significant change in therapy
- 12320** ☐ First BMD, age 70+ ☐ 5 years since prior BMD, age 70 years+ with no to mild osteopenia (T-score 0 to -1.5) on prior BMD
- 12312** ☐ 12 mths+ since prior BMD (please also tick description) ☐ Male hypogonadism ☐ Female hypogonadism > 6mths before age 45
- ☐ Prolonged glucocorticoid therapy (as per MBS) ☐ Conditions associated with excess glucocorticoid secretion
- 12306** ☐ 24 mths+ since prior BMD (please also tick description) ☐ 1 or more fractures after minimal trauma ☐ Scans 2 years+ with Z score -1.50 or lower, or a T score -2.50 or lower
- ☐ Monitoring osteoporosis proven by prior BMD
- 12315** ☐ 24 mths+ since prior BMD (please also tick description) ☐ Primary hyperparathyroidism ☐ Proven malabsorptive disorders (Crohns, Coeliac)
- ☐ Conditions associated with thyroxine excess ☐ Rheumatoid arthritis ☐ Chronic liver / renal disease
- 12322** ☐ 24 mths+ since prior BMD. Age 70+ and has moderate to marked osteopenia (T-score -1.5 to -2.5) on prior scan.

HOSPITAL PRACTICE
MATER PRIVATE HOSPITAL

76 Willetts Road, North Mackay

COMMUNITY PRACTICES
FOURWAYS

96 Nebo Road, West Mackay

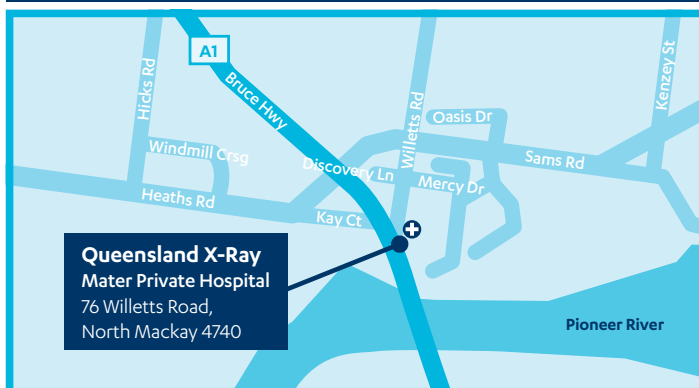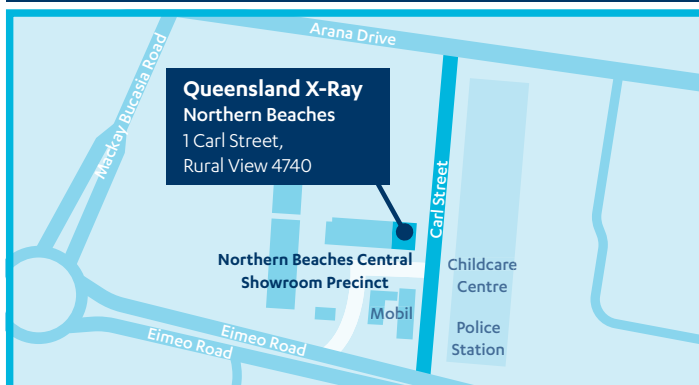NORTHERN BEACHES

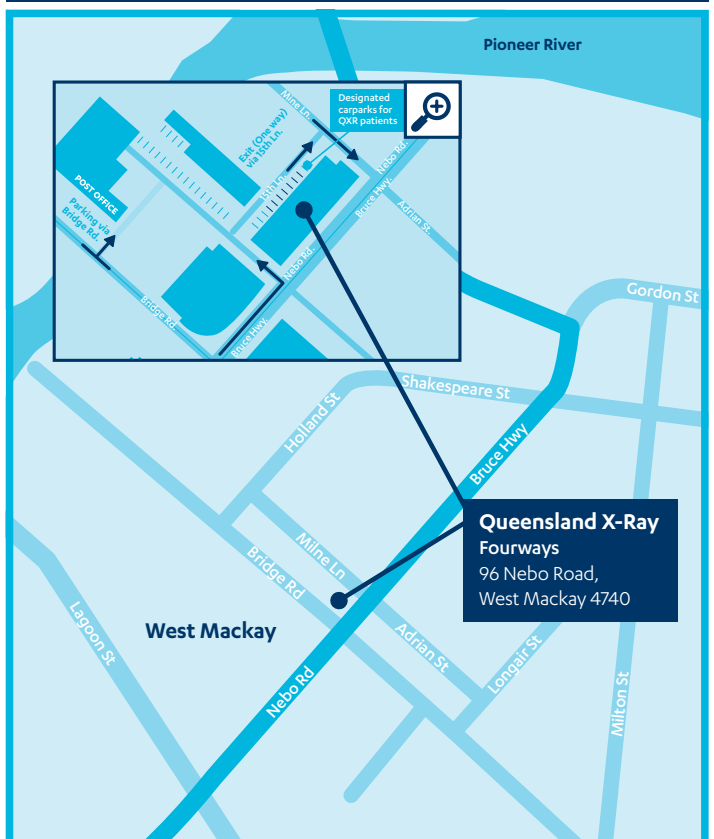
1 Carl Street, Rural View

Ph: 4965 6200

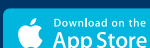Fax: 4942 7506

CONE BEAM	PLAIN X-RAY	EOS IMAGING	OPG	FLUOROSCOPY	CT SCAN	ULTRASOUND	DUPLEX ULTRASOUND	NUCHAL TRANSLUCENCY	MAMMOGRAPHY	NUCLEAR MEDICINE	BONE DENSITOMETRY	MRI
	•		•	•	•	•	•	•	3D*	•		•
•	•	•	•		•	•					•	•
	•				•	•						

MATER PRIVATE HOSPITAL

FOURWAYS

NORTHERN BEACHES


Access your images and results online. For more information, please visit qldxray.com.au/patients/online-access-patient-portal

DOWNLOAD THE QXR PATIENT APP



Queensland X-Ray stores your images for FIVE years. Visit us for all your medical imaging and create a complete and highly secure five-year electronic radiology record which your doctor can access 24/7.

* Contrast Enhanced Mammography

Queensland X-Ray Pty Ltd and Queensland X-Ray Hospital Partnership No 23 trading as Queensland X-Ray (a registered business name of Queensland X-Ray Pty Ltd ABN 40 094 502 208). 7022B 09/25

Printed on Supreme Laser which has the following environmental credentials:

